

long-term studies show survival rates for one-piece ceramic implants of over 95%⁽³²⁻³⁴⁾.

Case presentation

PRESURGICAL CONSIDERATIONS:

This 57-year old female patient was referred to our clinic (SWISS BIOHEALTH CLINIC) in Kreuzlingen Switzerland, after presenting to Dr. Corbin Popp, Denver, CO, USA. She had a long history of dental therapy and several dental and systemic symptoms including temporomandibular joint disorders (TMD), bite misalignment/disharmony after orthognathic surgery, multiple symptomatic titanium implants, and severe health issues. Years ago, she had a double jaw/ bimaxillary surgery performed, that was supported with a fixed orthodontic treatment afterwards. The orthodontic devices had been removed one year prior to her introduction to the clinic, but the titanium plates from the orthognathic surgery remained in place. Since her first bimaxillary surgery, she had been suffering from chronic pain in her head and jaw, skin rashes, skin sores and a continual, intense feeling of pressure in her head.

A MELISA test revealed a sensitivity to Titanium and in addition her chronic facial skin reaction gave cause for concern that there was a metal allergy. At this point the patient was then referred to SWISS BIOHEALTH CLINIC, Kreuzlingen Switzerland, to treat her missing teeth and remove the metal of the bimaxillary surgery.

Prior to treatment at the SWISS BIOHEALTH CLINIC, TMD treatment with bMAGO (bioesthetic Maxillary Anterior guidance Orthotic) to reach stable condyle position (SCP) and dissolvment of TMD symptoms was performed by Dr. Popp.

At the start of surgical treatment her vitamin D3 level was at 91,2ng/l and her LDL at 1,4 g/l. In order to guarantee optimal bone metabolism, patients at the SWISS BIOHEALTH CLINIC are given a vitamin D level of at least 70 ng/ml. Studies have shown that an LDL value of less than 1.2 g/L has a positive effect on the healing rate of implants.

The intraoral and x-ray investigation (Figure 1-2) showed the placement of numerous metallic plates, five titanium implants, several tooth fragments and leftovers, insufficient metallic crowns and dental restorations. The vitality test of tooth 14 was negative and the tooth displayed a large cyst.

Surgical treatment

Following the concept of the SWISS BIOHEALTH CLINIC and the request of the patient, all metals were removed (metallic plates and titanium implants) and her missing teeth were replaced with metal-free, zirconia implants (SDS Swiss Dental Solutions).

The surgery was performed over two consecutive days.

Day 1: Under sedation of the patient, oral surgeon Dr. Josephine Tietje removed ten metallic osteosynthesis plates and forty-two screws. The access was chosen to follow the old scars in the vestibulum, partially removing and correcting the course and the thick scar tissue. In order not to restrict the blood supply to the gum tissue, minimally invasive incisions were made. Due to the long period of time that the osteosynthesis plates were in place, bone had already grown over them. (Figure 3). The plates were carefully uncovered using piezo-surgery and fine hand instruments (Figure 4). All wounds were disinfected with ozone,

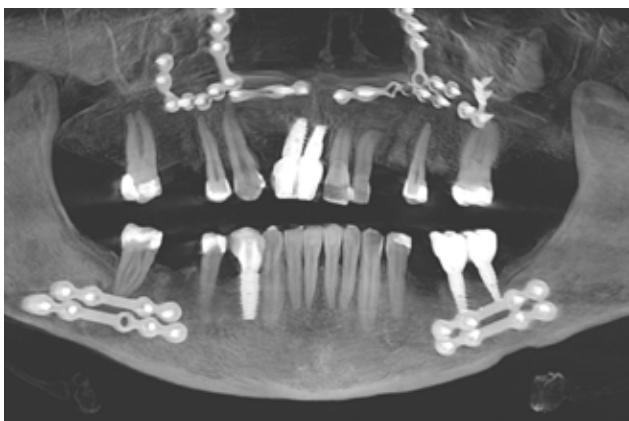

Figure 1: Panoramic x-ray (from 3D scan) 11/2018

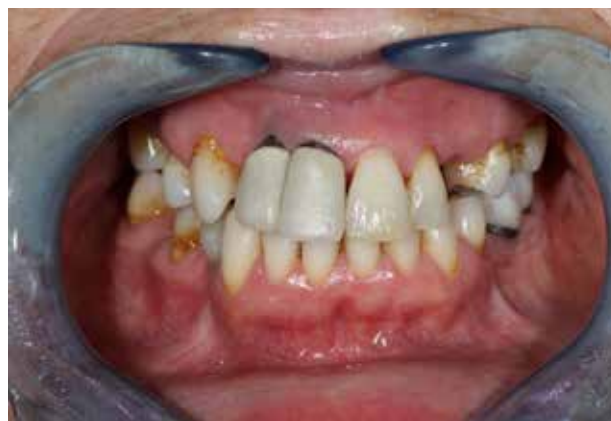

Figure 2: Intraoral situation at time of first introduction to our clinic

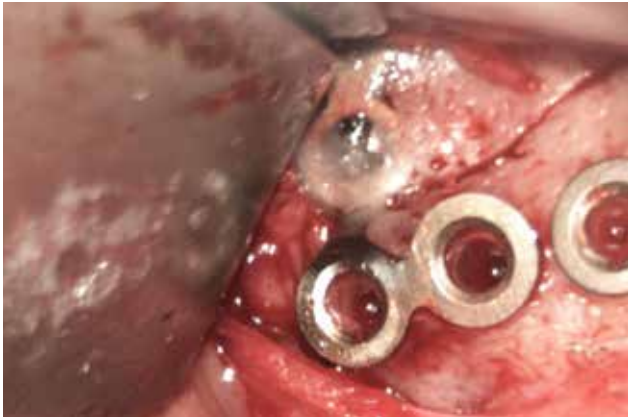


Figure 3: Intraoperative display of the metallic plates



Figure 4: Display of the removed metal

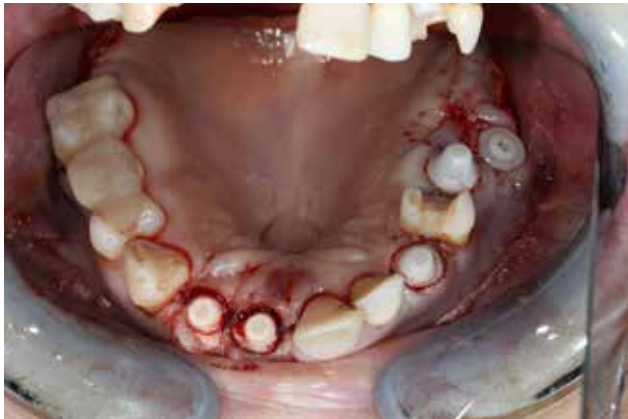

Figure 5: Implant placement of the upper jaw

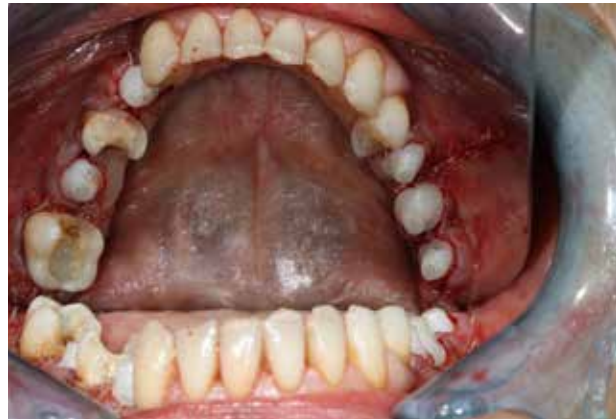

Figure 6: Implant placement of the lower jaw

A-PRF membranes (Mectron *Æ*, Dr. Joseph Choukroun) were applied to support the healing and the incisions were closed with Atramat (mednaht *Æ*) suture material. At this point of time, the sedation was ended and the surgery was continued with the patient awake.

The titanium implants in the lower jaw (region 18, 19, 28) were removed using piezo-surgery and the “Implant Removal Kit” (Neobiotech *Æ*). In addition, a root fragment was removed in region of tooth 20. Five ceramic SDS-implants were placed in the lower jaw (region 18, 19, 20, 28, 30). The implants were immediately restored chairside with fixed temporaries made from Luxatemp (DMG *Æ*) and cemented with Durelon (3MTm *Æ*).

Day 2: On the second day of surgery, Dr. Ulrich Volz, specialist and pioneer of ceramic implantology, removed the titanium implants in the upper jaw (region 7 and 8). Since the previous implant positioning was not optimal prosthetically and surgically, bone grafting had to be performed to fill the former drill holes. Bone chips were collected and mixed with the solution of A-PRF in order to generate sticky bone that forms a flexible bone graft. Connective tissue was collected from the maxillary tubal area and placed in the front region to

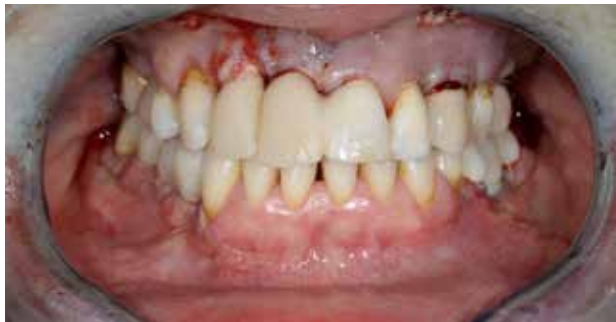

Figure 7: Intraoral situation after placement of all temporaries

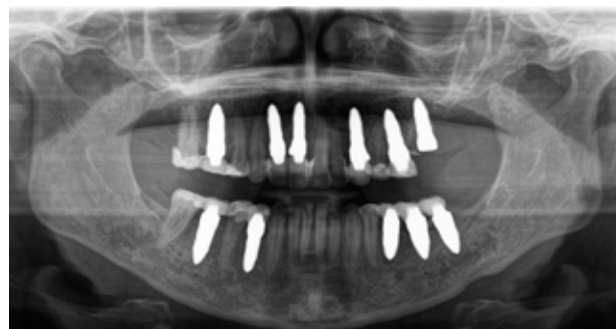

Figure 8: Postoperative panoramic x-ray

enhance the aesthetic result. Tooth 14 was extracted, the cyst thoroughly cleaned with hand instruments and six ceramic SDS-implants were placed (regions 3, 7, 8, 11, 13 and 14).

The aggressive dynamic thread design of the SDS ceramic implant proved to be very useful in this case, as it allows individual positioning, allowing the anterior implants to be placed independently of the previous drilling. To place a long and stable implant in region 14, an internal sinus floor elevation was performed and the implant gained the necessary stability by anchoring in the sinus floor. Figures 5-8 show the situation after completion of the surgery.

Immediately after completion of the operation, the patient felt relieved from her persistent head pressure. Slight swelling developed, but it decreased continuously after the third day after the operation.

Prosthetic treatment

Temporary prosthetic restoration immediately after surgery:

In addition to the removal of the metal implants and their prosthetic parts, all remaining conservable teeth that had good vitality (teeth 2, 4, 12, 21, 29, 31) were consistently treated prior to surgery by replacing inadequate fillings and caries. After finishing the surgical intervention, chair-side long-term temporary restorations were made in blocks, connecting all neighboring teeth and one-piece implants with good primary stability (temporaries ##2-4, 7-8, 11-13, 18-21, 28-31). Luxatemp (DMG) was used as temporary material. The temporaries were fixed on natural teeth with highly biocompatible adhesive. Flow composite (Saremco) and Durelon (3M) were used simultaneously as cement on the ceramic implants. In addition, the temporaries on the teeth 7 and 8 were connected adhesively to the neighboring teeth.

The occlusion was adapted to the habitual bite, which was prepared beforehand by means of appliance therapy (see above). All occlusal and articulating contacts of the temporaries were removed in order to exclude harmful forces during the healing phase. The patient was advised to only chew on very soft food for eight weeks after surgery.

Post surgical considerations

Two months after the surgery at the SWISS BIOHEALTH CLINIC a new full time bMAGO (Eclipse, Dentsply Sirona) was applied to resolve reoccurring TMJ symptoms, balance occlusion, reach SCP and simulate the targeted Vertical Distance of Occlusion (VDO).

Final fixed prosthetic restoration with ceramic

After a healing phase of five months, all implants showed good osseointegration, shown by a positive percussion test

and good periost values (all between -4 and -6.5 indicating optimal integration). Thus, final prosthetic treatment for fixed prosthetics could be started, which was performed by Dr. Corbin Popp (Denver, CO, USA).

The functional and aesthetic rehabilitation presented several challenges that had to be addressed. The reduced anterior ridge in the upper anterior region, the large discrepancy in the patients upper and lower arches, achieving a balanced bite with proper anterior or group function guidance to protect her new implants, and to provide comfort to her TMJ as simulated in her well-adjusted bMAGO. The final challenge was matching her existing natural teeth to the new implant ceramic crowns considering the amount of reduction needed on otherwise healthy teeth.

Final restoration

An initial anterior wax up was completed by Andre's Dental Studio (Dana Point, CA) prior to the restorative treatment. Original temporaries were removed and the preparations were revised on the implants and natural teeth. The implant shoulder of all implants of Swiss Dental Solutions can be prepared with a diamond bur to adapt the preparation margin to gingival level.

New Luxatemp temporaries were fabricated chairside from the new waxed-up model and the lower anterior teeth were slightly enlarged chairside to ensure a balanced contact at a specific VDO for optimal restorations. After a few weeks the patient was very satisfied with the it.

A ceramic abutment on ceramic implant 16 was cemented, resulting in the same shape and functionality as a one-piece ceramic SDS implant.

We then replaced the posterior temporaries chairside based off the wax up at this same VDO. Afterwards new records at this VDO were taken for the next set of temporary anterior restorations.

A revised wax up with minor adjustments was performed by Andre's Dental Lab; Dana Point, CA. New laboratory-fabricated temporaries made of IPS e.max (lithium disilicate) were fabricated and placed to restore the bite and function and achieve appealing aesthetics. This was the final set of temporaries on the upper anterior implants and crowns to help determine proper shading of the implants 7 and 8 implants and the natural tooth crowns and 10 natural tooth crowns. The lower anterior teeth 22 - 27 and the upper right canine tooth no. 6 were restored with a direct composite injection molding technique RSVP based on the final wax-up.

In favor of a minimally invasive approach, no ceramic inlays or onlays were used at that time to preserve the tooth structure, as the history of devitalization of the patients teeth after restorative work is known.

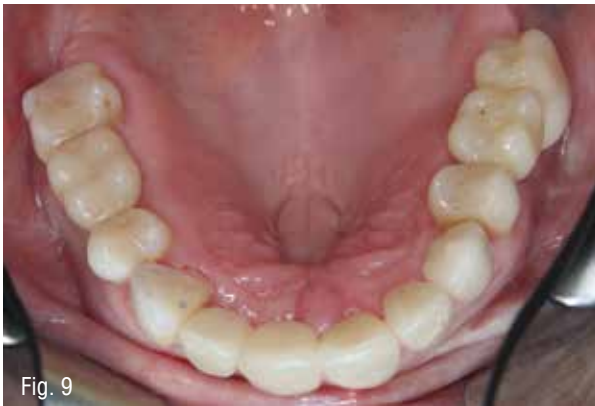

Fig. 9

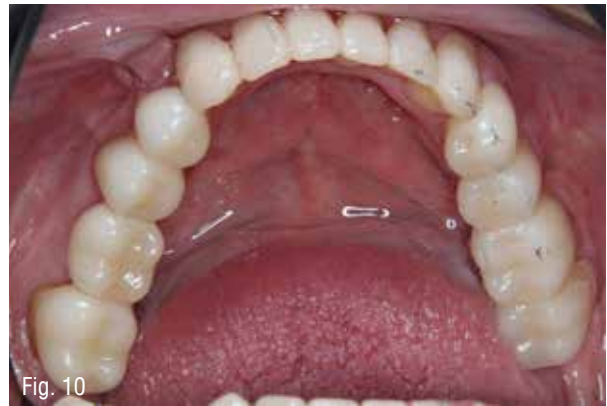

Fig. 10

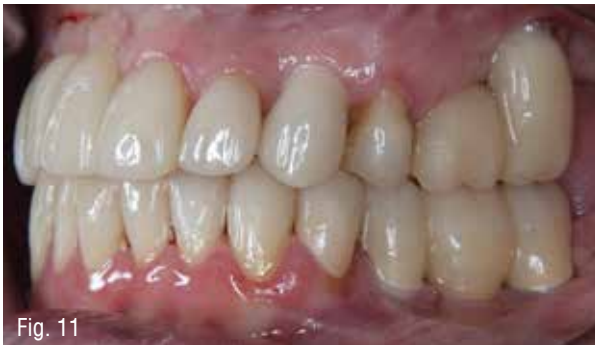

Fig. 11

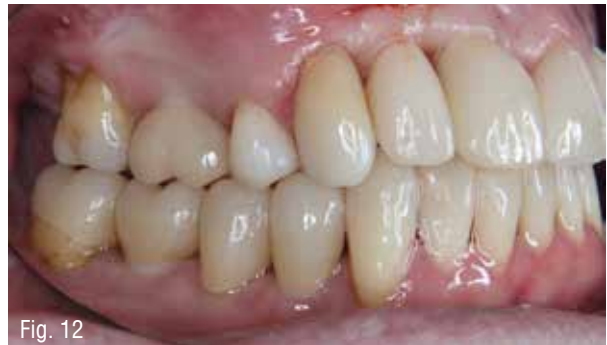

Fig. 12

After placing the temporary anterior crowns (IPS e.max), the final posterior crowns made of layered zirconium dioxide (region 3, 13, 14, 18, 28-31) were cemented and direct composite restorations were placed on the natural teeth (region 6, 2, 4, 12, 22-27) using the same techniques as described above. In the following restorative phase, the patient demonstrated her satisfaction with the function and esthetics of the anterior region, so that the IPS e.max temporary restorations on the SDS implants and natural teeth were replaced by layered ceramic zirconia crowns, except for implant 11, which remained in place due to satisfactory shading in IPS e.max Adjacent implants received connected crowns according to the SDS protocol and were cemented with Ketac Cem (3M). The connected crowns have several advantages without significant downsides. Since ceramic implants are highly osseointegrated and immobile, no individual crowning is necessary as with natural teeth, which have an individual movement within the natural alveolus. The bonded crowns result in higher stability, friction and less problematic areas in terms of periodontal hygiene.

Bite registration happened in centric relation after appliance therapy (bMAGO) to ensure SCP (Stable Condylar Position) per OBI (Orthognathic Bioesthetics International) bioesthetic therapy.

Occlusal and functional contacts were adjusted to axial loading forces and in a way to ensure maximum longevity and function. Implants were adjusted in slight infra-occlusion (~10µm) in soft occlusion

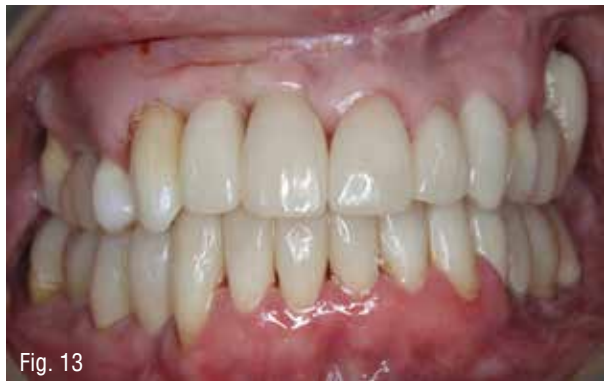

Fig. 13

Figures 9 – 13: Showing the final restoration

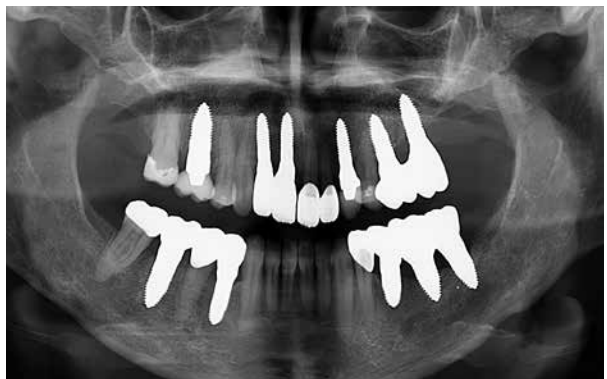
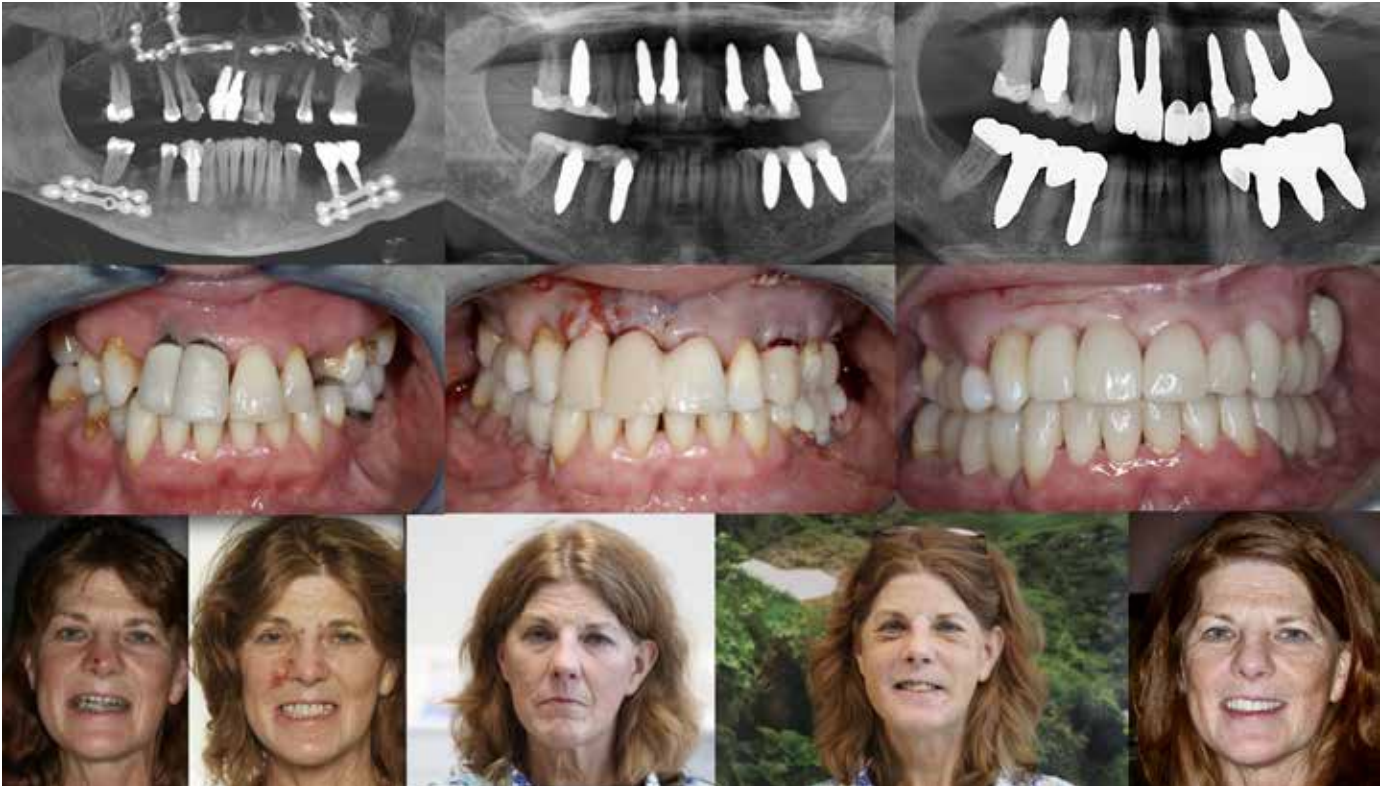
Figure 14: Panoramic x-ray after final prosthetic treatment

restorations with ceramic inlays or onlays and a veneer on tooth 6 in the future. She is very happy and feels much better.



Conclusion

In a written testimonial to the Swiss Biohealth Clinic the patient states after the procedures: "(...) Prior to my procedures I was losing energy, had trouble thinking straight, and couldn't relax; my coordination was poor and getting worse with time. Additionally, my eyes were sensitive to light, my ears were sensitive to sound, and my skin was very sensitive to touch. I was also emotionally sensitive and very anxious. I constantly felt like I had a metal rod running between my ears. If exposed to too much Wi-Fi, smart meters, smart-phones, or anything with EMFs, all my symptoms would get much worse. The "metal rod" would seem to get larger in diameter and throb, radiating throughout my entire head. After my first day of surgery I could feel the pressure in my head reduce and my body already start to relax for the first time in a very long time. The "metal rod" feeling in my head was gone by that night. About one or two days after my procedures, I noticed that my heart was no longer racing and I had my balance and coordination back when I wake up in the morning. (...) I am feeling much calmer and can relax, my energy is returning, I am sleeping much better and longer, my ears and eyes are losing their sensitivity. (...) At Swiss BioHealth I was very well taken care of. Every person at the clinic was very kind and competent. They all have a good understanding of what their patients are experiencing, and are there to help. I have no doubt going to Swiss BioHealth to have the metal in my mouth removed, non-reactive implants placed and cavitations cleaned out was the best decision for my health. I am so grateful to my dentists in the United States for being the kind of dentists who look deeply into the health of their patients'

mouth. (...) I am also very grateful to Dr. Volz for all the time and effort it must have taken to develop non-reactive implants as well as the careful attention to detail regarding pre- and post-surgical treatments to aid in healing. You are all amazing – Thank You So Much!" - J.H., Casper, WY, USA

The All in One Concept done at the Swiss Biohealth Clinic and the excellent final prosthetic restoration (in this case done by Dr. Corbin Popp, Denver CO, USA) not only rehabilitates the patients functionally and aesthetically in an optimal way and in the shortest possible time, but also restores their quality of life and health. ■

The Authors



Dr. Karl Ulrich Volz is founder and former President of the ISM[®] International Society of Metal-Free Implantology, and founder of the dental clinics Bodensee Zahnklinik and Tagesklinik Konstanz. In 2001, he developed the first market-ready ceramic implant and was also the one who developed all of SDS Swiss Dental Solutions' implant designs for a wide range of indications. He went on to become the dentist to install the most ceramic implants in the world. Thanks to this pioneering achievement, he is arguably the most experienced and well-known biological dentist in Europe, and has developed unique treatment methods and surgery concepts which only became possible through the concurrent use of biological and immunological enhancement and accompaniment protocols. His treatment successes, publications, and interna-tional talks have sparked a new trend in dentistry and led to the fact that a large percentage of his patients are themselves dentists, doctors, and non-medical practitioners. He currently leads the biological dentistry department in the SWISS BIOHEALTH CLINIC in Kreuzlingen, Switzerland.



DR. Corbin Popp was raised by a dentist in Lincoln, Nebraska where he attended the University of Nebraska and accepted the prestigious Fulbright Scholarship to Germany for a year of study. Returning to dental school –only after taking 10 years to peruse a professional dance and Broadway career, Corbin was Top of the Class, and the Resident of The Year from the Arizona School of Dentistry and Oral Health and CU Anschutz GPR. Dr. Popp is a strong advocate of the Swiss Biohealth Concept and ceramic implantology. Dr. Popp currently is practicing at Bidentist Denver.



Dr. Josephine Tietje, born in Hamburg, Germany, in 1991, has studied dentistry at the University of Muenster, achieving the best state examinations of her semester and has successfully specialized in oral surgery. She has treated patients in a renowned private practice, a large maxillofacial practice and the central oral- and maxillofacial clinic in Bremen. Since the beginning of 2018, Dr. Josephine Tietje has placed several hundred ceramic implants at the Swiss Biohealth Clinic. She is responsible for all surgical procedures – be it bone grafting, implant placement, sinus floor elevation, cavitation treatment or complex wisdom tooth and metal removal.



Paul Kilanowski, DMD. Since the beginning of his dentistry studies at university, Paul Kilanowski underwent additional education and training in Implantology. Later, he continuously took part in numerous trainings, among them a one year implantological curriculum (DGO). Soon he will obtain his doctorate (Dr. med. dent.) at the Clinic of Oral and Maxillofacial Surgery of the FAU Erlangen–Nurnberg. Since 2017, Paul Kilanowski is trained in ceramic Implantology and biological dentistry by Dr. Volz personally at the SWISS BIOHEALTH CLINIC. He practices and continues learning this technique ever since. His focus is the head–neck area, the bite and the related detoxification. His therapeutical special field within biological dentistry covers total prosthetic rehabilitation regarding biological principles, the bite adjustment and aesthetic dentistry.



Dr. Rebekka Hueber, born in Germany, has completed her studies in dentistry at Ludwig–Maximilians–University in Munich with surgical top marks. Shortly thereafter, she obtained her doctorate in the surgical clinic, Klinikum rechts der Isar, at the Technical University in Munich. With great passion she completed the four–year specialization in well–known oral surgery practices in Munich and Rosenheim, Germany. She was also involved in dental aid in Peru, South America. Most recently, she successfully led the surgical department of a well–renowned private dental clinic as a specialist in oral surgery and implantology in Germany and implemented the concept of the Swiss Biohealth Clinic as a side department there. With great enthusiasm and experience in the field of medicine, she devotes herself to biological dentistry and has already been able to deepen her knowledge through numerous advanced training courses. She has completed the educational program of the specialization of the SDS Curriculum and is trained in ceramic implantology, the use of PRF and iPRF, Neural therapy and recovery of heavy metal, prosthetics on SDS implants and the Swiss Biohealth Concept. Since beginning of 2019 she is an Oral surgeon in Dr. Volz Swiss Biohealth Clinic and scientific researcher, as well as member in the Swiss Biohealth Academy in Kreuzlingen. She has completed the educational program of the SDS Curriculum “Ceramic Implants and Biological Dentistry” and other programs of biological dentistry.

References

1. Rouck T de, Collys K, Cosyn J. Immediate single-tooth implants in the anterior maxilla: a 1-year case cohort study on hard and soft tissue response. *J Clin Periodontol.* 2008;35(7):649–57. doi:10.1111/j.1600-051X.2008.01235.x
2. Buser D, Chappuis V, Belser U, Chen S. Implant placement post extraction in esthetic single tooth sites: when immediate, when early, when late? *Periodontology* 2000. 2017;201784–102. doi:10.1111/prd.12170
3. Chen ST, Buser D. Clinical and esthetic outcomes of implants placed in postextraction sites. *Int J Oral Maxillofac Implants.* 2009;24 Suppl186–217.
4. Cosyn J, Lat L de, Seyssens L, Doornewaard R, Deschepper E, Vervaeke S. The effectiveness of immediate implant placement for single tooth replacement compared to delayed implant placement: A systematic review and meta-analysis. *J Clin Periodontol.* 2019;46 Suppl 21224–41. doi:10.1111/jcpe.13054
5. Mello CC, Lemos CAA, Verri FR, Dos Santos DM, Goiato MC, Pellizzer EP. Immediate implant placement into fresh extraction sockets versus delayed implants into healed sockets: A systematic review and meta-analysis. *Int J Oral Maxillofac Surg.* 2017;46(9):1162–77. doi:10.1016/j.ijom.2017.03.016
6. Schwartz-Arad D, Chaushu G. Placement of implants into fresh extraction sites: 4 to 7 years retrospective evaluation of 95 immediate implants. *J Periodontol.* 1997;68(11):1110–6. doi:10.1902/jop.1997.68.11.1110
7. Chrcanovic BR, Albrektsson T, Wennerberg A. Dental implants inserted in fresh extraction sockets versus healed sites: a systematic review and meta-analysis. *J Dent.* 2015;43(1):16–41. doi:10.1016/j.jdent.2014.11.007
8. Lindeboom JAH, Tjiook Y, Kroon FHM. Immediate placement of implants in periapical infected sites: a prospective randomized study in 50 patients. *Oral Surg Oral Med Oral Pathol Oral Radiol Endod.* 2006;101(6):705–10. doi:10.1016/j.tripleo.2005.08.022
9. Werbit MJ, Goldberg PV. The immediate implant: bone preservation and bone regeneration. *Int J Periodontics Restorative Dent.* 1992;12(3):206–17.
10. Wheeler SL, Vogel RE, Casellini R. Tissue preservation and maintenance of optimum esthetics: a clinical report. *Int J Oral Maxillofac Implants.* 2000;15(2):265–71.
11. Block MS, Mercante DE, Lirette D, Mohamed W, Ryser M, Castellon P. Prospective evaluation of immediate and delayed provisional single tooth restorations. *J Oral Maxillofac Surg.* 2009;67(11 Suppl):89–107. doi:10.1016/j.joms.2009.07.009
12. Pip kurz & schmerzlos. Sofortbelastung und Sofortversorgung. *Praktische Implantologie und Implantatprothetik [Internet].* 2015;(3):24–47. Available from: https://www.dgoi.info/wp-content/uploads/2016/04/pip_3_2015-Sofortbelastung-und-Sofortversorgung.pdf
13. Ortega-Martínez J, Pérez-Pascual T, Mareque-Bueno S, Hernández-Alfaro F, Ferrés-Padró E. Immediate implants following tooth extraction. A systematic review. *Med Oral Patol Oral Cir Bucal.* 2012;17(2):e251–61. doi:10.4317/medoral.17469
14. Rosenquist B, Grenthe B. Immediate placement of implants into extraction sockets: implant survival. *Int J Oral Maxillofac Implants.* 1996;11(2):205–9.
15. Hui E, Chow J, Li D, Liu J, Wat P, Law H. Immediate provisional for single-tooth implant replacement with Brånemark system: preliminary report. *Clin Implant Dent Relat Res.* 2001;3(2):79–86. doi:10.1111/j.1708-8208.2001.tb00235.x
16. Polizzi G, Grunder U, Goené R, Hatano N, Henry P, Jackson WJ, Kawamura K, Renouard F, Rosenberg R, Triplett G, Werbit M, Lithner B. Immediate and delayed implant placement into extraction sockets: a 5-year report. *Clin Implant Dent Relat Res.* 2000;2(2):93–9. doi:10.1111/j.1708-8208.2000.tb00111.x